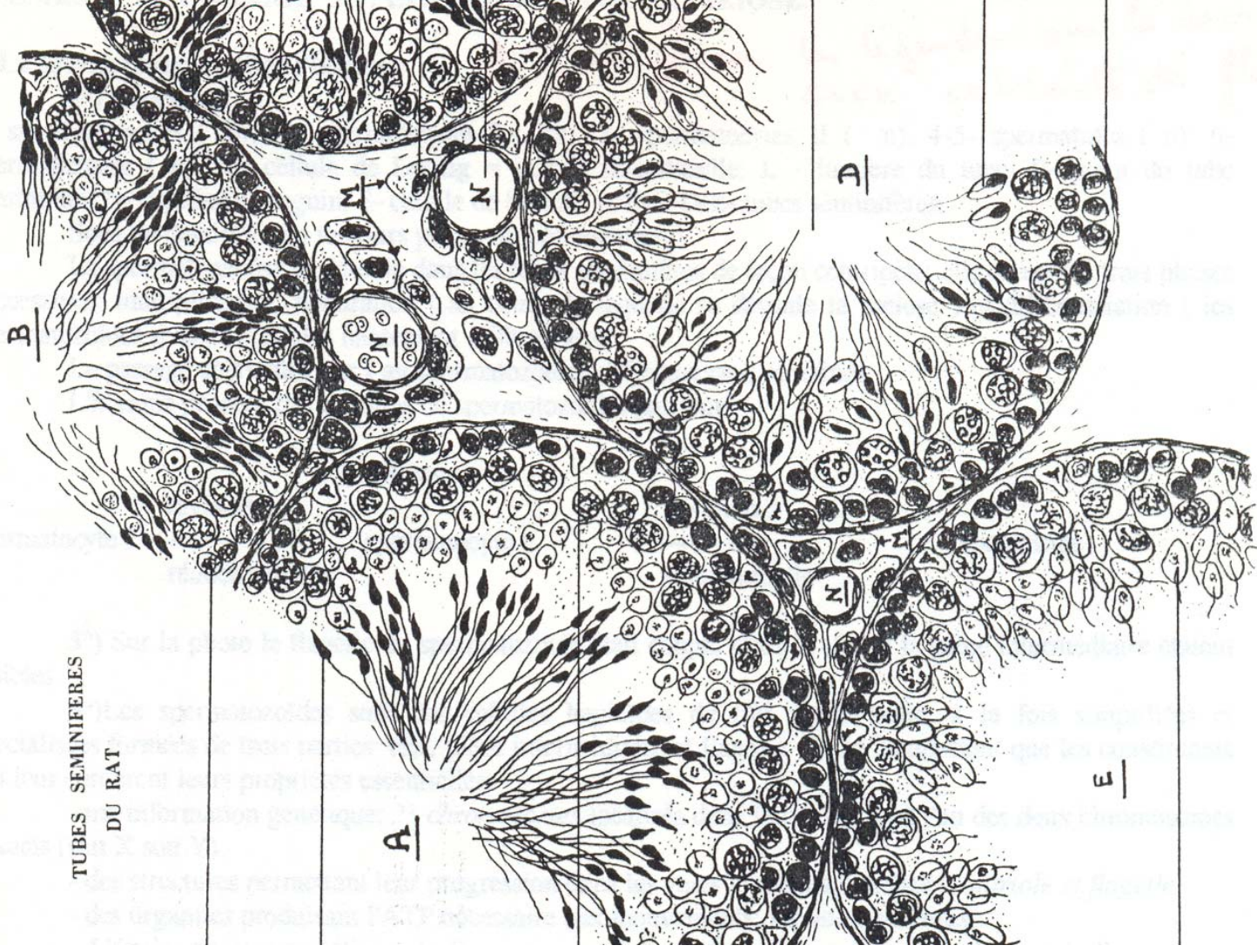


TUBES SEMINIFERES
DU RAT



Commentaire :